

Michigan Ear Institute

# Facial Nerve Problems



[www.michiganear.com](http://www.michiganear.com)

DOCTORS

**Dennis I. Bojrab, MD**  
**Seilesh C. Babu, MD**  
**John J. Zappia, MD, FACS**  
**Eric W. Sargent, MD, FACS**  
**Eleanor Y. Chan, MD**  
**Robert S. Hong, MD**  
**Ilka C. Naumann, MD**  
**Candice C. Colby, MD**  
**Christopher A. Schutt, MD**

LOCATIONS

**Providence Medical Building**  
30055 Northwestern Highway  
Suite 101  
Farmington Hills, MI 48334

**Beaumont Medical Building**  
3555 W. Thirteen Mile Road  
Suite N-210  
Royal Oak, MI 48073

**Oakwood Medical Building**  
18181 Oakwood Blvd.  
Suite 402  
Dearborn, MI 48126

**Providence Medical Center**  
26850 Providence Parkway  
Suite 130  
Novi, MI 48374

**248-865-4444 phone**  
**248-865-6161 fax**

## WELCOME

*Welcome to the Michigan Ear Institute, one of the nation's leading surgical groups specializing in hearing, balance and facial nerve disorders. The Michigan Ear Institute is committed to providing you with the highest quality diagnostic and surgical treatment possible.*

*Our highly experienced team of physicians, audiologists and clinical physiologists have established international reputations for their innovative diagnostic and surgical capabilities, and our modern, attractive facility has been designed with patient care and convenience as the foremost criteria.*

*It is our privilege to be able to provide care for your medical problems and we will strive to make your visit to the Michigan Ear Institute a positive and rewarding experience.*

## **A DISCUSSION OF FACIAL NERVE PROBLEMS**

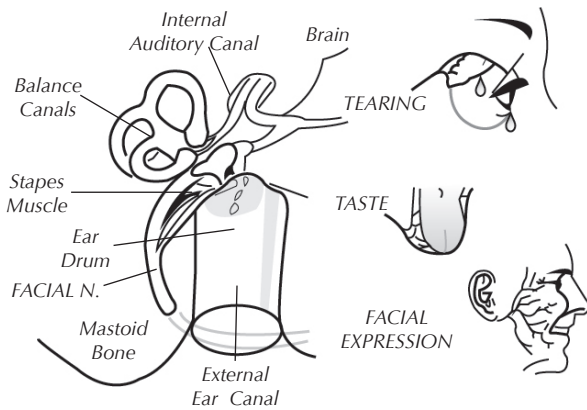
Twitching, weakness or paralysis of the face is a symptom of some disorders involving the facial nerve. It is not a disease in itself. The disorder may be caused by many different diseases, including circulatory disturbances, injury, infection or a tumor.

Facial nerve disorders are accompanied at times by a hearing impairment. This impairment may or may not be related to the facial nerve problems.

## **FUNCTION OF THE FACIAL NERVE**

The facial nerve resembles a telephone cable and contains hundreds of individual nerve fibers. Each fiber carries electrical impulses to a specific facial muscle. Acting as a unit this nerve allows us to laugh, cry, smile or frown, hence the name, "the nerve of facial expression". Each of the two facial nerves not only carries nerve impulses to the muscles of one side of the face, but also carries nerve impulses to the tear glands, saliva glands, to the muscle of a small middle ear bone (the stapes) and transmits taste fibers from the front of the tongue and pain fibers from the ear canal. As such, a disorder of the facial nerve may result in twitching, weakness or paralysis of the face, dryness of the eye or the mouth, loss of taste, increased sensitivity to loud sound and pain in the ear.

An ear specialist is often called upon to manage facial nerve problems because of the close association of this nerve with the ear structures. After leaving the brain the facial nerve enters the temporal bone (ear bone) through a small bony tube (the internal auditory canal) in very close association with the hearing and balance nerves. Along its inch and a half course through a small bony canal in the temporal bone



the facial nerve winds around the three middle ear bones, in back of the eardrum, and then through the mastoid to exit below the ear. Here it divides into many branches to supply the facial muscles. During its course through the temporal bone the facial nerve gives off several branches: to the tear gland, to the stapes muscle, to the tongue and saliva glands and to the ear canal.

## DIAGNOSIS OF A FACIAL NERVE DISORDER

Abnormality of facial nerve function may result from circulatory changes, infections, tumors, or injuries. An extensive evaluation is often necessary to determine the cause of the disorder and localize the area of nerve involvement.

### Hearing Test

Tests of hearing are done to determine if the nerve disorder has involved the delicate hearing mechanism. When the face is totally paralyzed a special hearing test (stapedius reflex) helps to localize the problem area.

## **“X-Rays”**

Scans are usually taken to determine if there is infection, tumor or bone fracture. (CT or MRI scans).

## **Tear Test**

A test of eye’s ability to tear may be helpful to determine the location of the facial nerve involvement.

## **Balance Test**

An ENG (electronystagmography) test of the balance system is advised in some cases to clarify the cause or location of the facial nerve disorder.

## **Electrical Tests**

There are three electrical tests of the facial nerve function that we may use: nerve excitability test, electroneurography and electromyography.

## **Nerve Excitability Test**

The facial nerve excitability test helps us to determine the extent of nerve fiber damage in cases of total paralysis. The test may be normal despite the paralysis, indicating a better outlook for return of function. In such cases the excitability test may be repeated every day or so to detect any change which would indicate progressive deterioration.

## **Electroneurography (ENoG)**

Electroneurography involves the use of a computer to measure the muscle response to electrical stimulation of the facial nerve. Recording electrodes are placed on the face and the facial nerve is stimulated with small electrical currents. Muscle contractions are recorded by the computer.

## **Electromyography**

Electromyography may be indicated in cases of long standing paralysis. This test helps us to know if the nerve and muscles are recovering. Tiny needles are used to measure the responses.

## EYE CARE

The most serious complication that may develop as the result of total facial nerve paralysis is an ulcer of the cornea of the eye. It is important that the eye on the involved side be protected from this complication by keeping the eye moist. Closing the eye with the finger is an effective way of keeping the eye moist. One should use the back of the finger rather than the tip in doing this to insure that the eye is not injured.

Glasses should be worn whenever you are outside. This will help prevent particles of dust from becoming lodged in the eye.

If the eye is dry, you may be advised to use artificial tears. The drops should be used as often as necessary to keep the eye moist. Ointment may be prescribed for use at bedtime.

At times it is necessary to tape the eyelid closed with tape. It is best for a family member to do this to insure that the eye is firmly closed and will not be injured by the tape.

If pain, redness or visual loss occurs despite lubrication, you should see an ophthalmologist (eye specialist) immediately.

In many cases where long standing paralysis is anticipated it may be necessary to insert a tiny gold weight into the eyelid or perform some other long standing procedure to help the eyelid close.

## BELL'S PALSY AND HERPES ZOSTER

### Bell's Palsy

The most common condition resulting in facial nerve weakness or paralysis is Bell's palsy, named after Sir Charles Bell who first described the condition. The underlying cause of Bell's palsy is not known, but it probably is due to a virus infection of the nerve. We know that the nerve swells in its tight bony canal. This swelling results in pressure on the nerve fibers and their blood vessels. Treatment is directed at decreasing the swelling and restoring the circulation so that the nerve fibers may again function normally.

### Herpes Zoster Oticus

A condition similar to Bell's palsy is herpes zoster oticus, "shingles" of the facial nerve. In this condition there is not only facial weakness but often hearing loss, unsteadiness and painful ear blisters. These additional symptoms usually subside spontaneously but some hearing loss may be permanent.

### Treatment

Treatment of the facial paralysis in these two conditions may be either medical or surgical.

### Medical Treatment

Medical treatment, (with steroids or antiviral medications), may be instituted to decrease the swelling and stimulate the circulation.

### Surgical Treatment

□ *Mastoid decompression of the facial nerve.* Surgical decompression of the facial nerve is indicated in cases of paralysis when the electrical tests show that the nerve function is deteriorating. This operation is performed under general anesthesia and requires hospitalization for two to four days. Through an incision behind the ear the rigid mastoid bone around



the swollen nerve is removed, relieving pressure so that the circulation may be restored.

The degree and rapidity of recovery of facial nerve function depends upon the amount of damage present in the nerve at the time of surgery. Recovery may take from 3 to 12 months and may not be complete. Fortunately, it is unusual to develop a hearing impairment following surgery but this depends on the extent of surgery needed in the individual case.

□ *Middle fossa facial nerve decompression.* At times deeper portions of the facial nerve are affected. In that case surgery may also involve an incision above the ear, with removal of a small portion of the skull. The need for this procedure can usually be determined by tests before surgery.

□ *Mastoid and middle cranial fossa facial nerve decompression.* This procedure is a combination of the previously described surgeries.

## **RISKS AND COMPLICATIONS OF FACIAL NERVE SURGERY**

### **Hearing Loss**

All patients notice some hearing impairment in the operated ear immediately following surgery. This is due to swelling and fluid collection in the mastoid and middle ear. This swelling usually subsides within 2 to 4 weeks and the hearing returns to its preoperative level. In an occasional case scar tissue forms and results in a permanent hearing impairment. It is rare to develop a severe impairment.

### **Dizziness**

Dizziness is common following surgery due to swelling of the inner ear structures. Some unsteadiness may persist for a few days postoperatively. On rare occasions dizziness is prolonged.

## **Related to Middle Fossa Approach**

The middle fossa approach to the facial nerve, necessary in some cases, is a more serious operation. Hearing and balance disturbances are more likely following this surgery. Permanent impairment is, nonetheless, uncommon.

*A hematoma* (collection of blood under the skin incision) develops in a small percentage of cases, prolonging hospitalization and healing. Reoperation to remove the clot may be necessary if this complication occurs.

*A cerebrospinal fluid leak* (leak of fluids surrounding the brain) – develops in an occasional case. Reoperation may be necessary to stop the leak.

*Infection* is a rare occurrence following facial nerve surgery. Should an infection develop after a middle fossa it could lead to meningitis, an infection in the fluid surrounding the brain. Fortunately, this complication is very rare.

*Temporary paralysis* of half of the body has occurred following middle fossa operation, due to brain swelling. This complication is extremely rare.

## **Related to Anesthesia**

Operations on the facial nerve usually are performed under general anesthesia. There are risks involved with any anesthesia and you should discuss this with the anesthesiologist.

## **INJURIES OF THE FACIAL NERVE**

A common cause of facial nerve injury is a skull fracture. This injury may occur immediately or may develop some days later due to nerve swelling. Injury to the facial nerve may occur in the course of operations on the ear. This complication, fortunately, is very uncommon. It may occur, however, when

the nerve is not in its normal anatomical position (congenital abnormality) or when the nerve is so distorted by the mastoid or middle ear disease that it is not identifiable. In rare cases it may be necessary to remove a portion of the nerve in order to eradicate the disease.

## **Treatment**

Treatment of an injured facial nerve may be medical or surgical, depending on the extent of the nerve damage.

## **Medical Treatment**

Medical treatment is the same as described for Bell's palsy.

## **Surgical Treatment**

*Mastoid Decompression of the facial nerve.*  
(Refer to page 8.)

*Middle fossa facial nerve decompression*  
(Refer to page 9.)

*Facial nerve graft* A facial nerve graft is necessary at times if facial nerve damage is extensive. A skin sensation nerve is removed from the neck and transplanted into the ear bone to replace the diseased portion of the facial nerve. Total paralysis will be present until the nerve re-grows through the graft. This usually takes 6 to 15 months. Some facial weakness may be permanent.

## **TUMORS**

### **Acoustic Tumors**

The most common tumor to involve the facial nerve is a nonmalignant fibroid tumor of the hearing and balance nerve, the acoustic tumor. Although there is rarely any weakness of the face before surgery, tumor removal sometimes results in weakness or paralysis. This weakness usually subsides in several months without treatment, occasionally it will be permanent.

It may may be necessary to remove a portion of the facial nerve in order to remove the acoustic tumor. Rarely, it may be possible to sew the nerve ends together at the time of surgery or to insert a nerve graft. At times a nerve anastomosis procedure is necessary later, connecting a tongue nerve to the facial nerve (hypoglossal facial anastomosis page 13 ). In either case the face is totally paralyzed until the nerve regrows which takes from (6 to 15 months).

## **Facial Nerve Neuroma**

A nonmalignant fibroid growth may grow in the facial nerve itself. This tumor may or may not produce a gradually progressive facial nerve paralysis. Removal of this facial nerve neuroma requires removing that portion of the facial nerve invaded by the tumor. Usually it is possible to graft it at the time with a skin sensation nerve from the neck. Total paralysis will last until the nerve regrows through the graft, usually requiring a period of 6 to 15 months. There will be some permanent facial weakness.

When the portion of the facial nerve nearest the brain is destroyed by the tumor, a facial reanimation procedure may be necessary (see below).

Removal of a facial nerve neuroma may necessitate removal of the inner ear structure. If this were necessary, it would result in a total loss of hearing in the operated ear and temporary severe dizziness. Persistent unsteadiness is uncommon.

## **FACIAL REANIMATION**

There are a number of surgical procedures that are helpful with facial paralysis. In some cases, repairing or decompressing an injured nerve is an important consideration. There are variety of other procedures that may be helpful to prevent drying or injury of the eye and assist in improving symmetry or even movement of the face although none of these procedures can create a perfectly normal appearance of the face.

## **Eyelid Surgery**

Implantation of gold into the upper eyelid can be helpful in counter balancing the lifting eyelid muscle. This helps to prevent dryness and irritation of the eye and helps to improve the appearance. Shortening of the lower lid or corners of the eyelid are sometimes performed at the same operation. Complications of these procedures are rare and may include bleeding, infection, droopy eyelid, extrusion of the implant and visual loss.

## **Hypoglossal-Facial Nerve Anastomosis**

Connecting a portion or all of the tongue nerve to the facial nerve may provide good tone to the face. Facial movements can also be obtained by attempting to move the tongue to the involved side when a smile is desired. Some degree of tongue weakness is expected which may affect speech or swallowing.

## **Temporalis Muscle Transposition**

Transferring one of the jaw muscles to the corner of the mouth can provide improvement of facial symmetry. Smiling is relearned by attempting to bite at the same time. Unlike hypoglossal-facial anastomosis, no tongue weakness is expected and chewing problems are rare. The surgeon always attempts to over correct the pull at the corner of the mouth. This over-correction and the significant face swelling usually resolve in 4-6 weeks. Rarely a very thick muscle may result in a bulge.

While facial reanimation surgery cannot provide a return to normal facial function, the improvement in eye protection and appearance is usually gratifying. Not infrequently, secondary procedures or revisions may be required to obtain the best results or modify results because of the passage of time.

## Miscellaneous

There are a variety of other operations that are sometimes performed by themselves or in combination with the above procedures. Such procedures may include a face lift or removal of excess skin at the brow or cheek. For patients who have some faulty return of facial function, selective cutting of facial nerve branches or facial muscles may be of benefit and are sometimes combined with other procedures to correct some of the anticipated weakness.

## OTHER FACIAL NERVE DISORDERS

### Facial Spasm

Surgery to correct this problem may involve **1)** intentional weakening of the nerve through an incision on the face which may also require a gold weight eyelid implant, or **2)** relieving pressure on the nerve adjacent to the brain. This operation includes risks of facial paralysis, hearing loss, dizziness, spinal fluid leak and stroke. **3)** An injection of Botox can give temporary relief. As always, you should discuss your proposed surgery in detail with your doctor.

### Mastoid Infection

Acute or chronic middle ear infections occasionally cause a weakness of the face due to swelling or direct pressure on the nerve. In acute infections the weakness usually subsides as the infection is controlled and the swelling around the nerve subsides.

Facial nerve weakness occurring in chronically infected ears is usually due to pressure from a cholesteatoma (skin-lined cyst). Mastoid surgery is performed to eradicate the infection and relieve nerve pressure. Some permanent facial weakness may remain.

## **Postoperative Facial Nerve Weakness**

Delayed weakness or paralysis of the face following reconstructive middle ear surgery (myringoplasty, tympanoplasty, stapedectomy) is uncommon, but occurs at times due to swelling of the nerve during the healing period.

Fortunately this type of facial nerve weakness usually subsides spontaneously in several weeks and rarely requires further surgery.

## **Hemifacial Spasm**

Hemifacial spasm is an uncommon disease of unknown cause which results in spasmodic contractions of one side of the face. Extensive investigation is necessary at times to establish the diagnosis correctly. In some cases, a hemifacial spasm is caused by irritation of the facial nerve near the brain. Examination of the nerve and correction of the irritation, if present, is possible by the retrolabyrinthine or retrosigmoid surgical approach. Facial nerve decompression (see Bell's palsy) may be beneficial.

In this operation the area between the brain and the inner ear is exposed by removing the mastoid bone behind the inner ear. The complications related to this surgery are the same as those for the middle fossa approach (Pages 9 and 10) .

## **Brain Disease**

Tumors and circulatory disturbances of the nervous system may cause facial nerve paralysis. The most common example of this is a stroke.

As opposed to other conditions listed in this booklet, in brain diseases there are usually many other symptoms which indicate the cause of the problem. Treatment is managed by the internist, neurologist or neurosurgeon.

## GENERAL COMMENTS

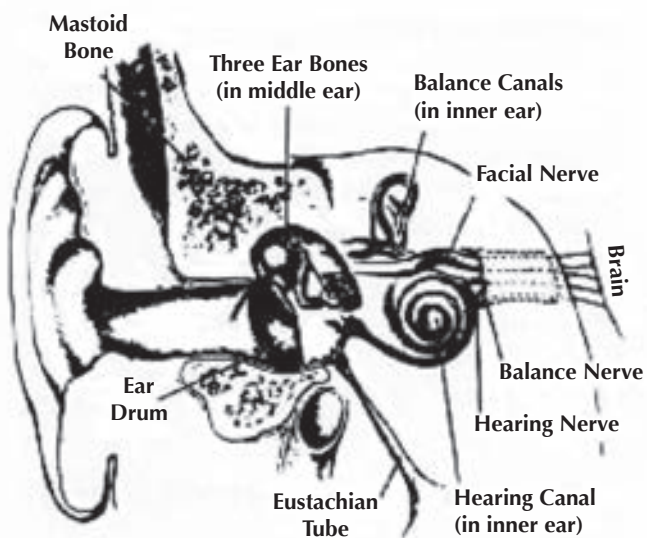
During the period of recovery of facial function, exercises may be recommended. Exercising the muscles by wrinkling the forehead, closing the eyes tightly and smiling forcefully may be beneficial.

Electrical stimulation of the facial muscles may be of some benefit.

As recovery of facial nerve function begins exercises may be recommended by your otologist.

Excerpt from materials prepared by the  
Otologic Medical Group Inc., Los Angeles, CA.





**Michigan Ear Institute**



## Facial Nerve Problems

---

Received by

---

Patient Signature

---

Date

For more information on the services and staff of the Michigan Ear Institute, call us at (248) 865-4444 or visit our web site at [www.michiganear.com](http://www.michiganear.com)

**Michigan Ear Institute**  
Providence Medical Building  
30055 Northwestern Highway #101  
Farmington Hills, MI 48334  
(248) 865-4444 phone  
(248) 865-6161 fax

NOTICE

St. John Providence complies with applicable Federal civil rights laws and does not discriminate on the basis of race, color, national origin, age, disability, or sex.

ATTENTION: If you speak a language other than English, language assistance services, free of charge, are available to you. Call 1-586-753-1888 (TTY: 1-313-343-3126).

ATENCIÓN: si habla español, tiene a su disposición servicios gratuitos de asistencia lingüística. Llame al 1-586-753-1888 (TTY: 1-313-343-3126).

ملحوظة: إذا كنت تتحدث انكر اللغة، فإن خدمات المساعدة اللغوية تتوافر لك بالمجان. اتصل برقم 586-753-1888 (رقم هاتف الصم والبكم: 1-313-343-3126).